

Kentucky ATC Newsletter

UKHealthCare

**Orthopaedic Surgery
& Sports Medicine**

Anatomic ACL Double-Bundle Reconstruction

Michael Sukay MD and Darren L. Johnson MD

Anterior cruciate ligament (ACL) tears are common injuries of the knee with approximately 250,000 tears occurring each year in the United States¹. The ACL consists of two functional bundles, the anteromedial (AM) and posterolateral (PL). In the past most ACL reconstructions have focused on recreating the anteromedial bundle, while reconstruction of the posterolateral bundle has not been routinely addressed.

The two bundles of the ACL are named according to their insertion on the tibial footprint. The AM bundle originates more proximally on the femoral site and inserts anteromedially on the tibial site, whereas the PL bundle originates more distally on the femoral site and inserts posterolaterally on the tibial site². In addition to these anatomic considerations, it has been shown that the two ACL bundles have different tension patterns³. The PL bundle loosens in flexion and tightens in extension, whereas the AM bundle demonstrates greater isometry throughout flexion and extension and reaches maximum tension between 60 and 90 degrees of flexion. The clinical importance of the reciprocal length and tension pattern of the AM and PL bundle is that, in any position of the knee, a portion of the ACL remains under tension and so confers stability to the knee joint.

Cadaveric biomechanical studies have shown that conventional ACL single bundle reconstructions more effectively restore anteroposterior knee stability, but did not provide sufficient stability in response to rotatory loads⁴. It has also been reported that ACL double bundle reconstruction provides better control against rotatory loads⁵. These data suggest that the anatomic ACL double bundle reconstruction may provide superior anteroposterior and rotational stability that ACL single-bundle reconstruction.

Technique

At our institution, our recommended technique for a failed single socket AM primary ACL reconstruction is revision to a double femoral socket and single tibial socket ACL reconstruction. The previous femoral tunnel may be used for the anatomic AM bundle if it is felt to be in the correct position and has a competent posterior wall (Figure 1). If the tunnel is in poor position then two entirely new femoral tunnels are made. The graft source is either bone patella tendon bone (BPTB) allograft or Achilles allograft. The allograft is customized to fit the existing femoral tunnel, and fixation is with an interference screw. Allograft is used in the previous tunnel because it can be cut to size to allow for filling of any tunnel dilation. Autograft tissue may be inadequate in size to fill a previous tunnel.

Next a posterolateral femoral tunnel is fashioned, using hamstring autograft to reproduce the normal posterolateral (PL) bundle of the ACL. It is fixed to the femur with an Endobutton (Smith & Nephew, Mansfield, MA) or a Biotenodesis screw (Arthrex, Naples, FL). The previous tibia tunnel often precludes a double tibial tunnel; therefore, we use a single expanded tibia tunnel. The previous tunnel is reamed by hand until all soft tissue is removed from the previous tunnel. Graft passage is accomplished by passing the PL bundle and fixing it to the femur. Then, while holding traction on the tibial side of the PL graft we pass the AM graft and fix it to the femur (Figure 2). Both grafts on the tibia side are then fixed with a bioabsorbable screw. We fix the graft with the knee held at 20 degrees of flexion.

Inside This Issue

- 1-2. **Anatomic ACL Double-bundle Reconstruction**
- 3-4 **Cardiovascular screening in athletes**
- 4-5 **What Is MRSA?**
- 5. **Meet Dr Christian Latterman, MD & Our Walk-in Clinic**

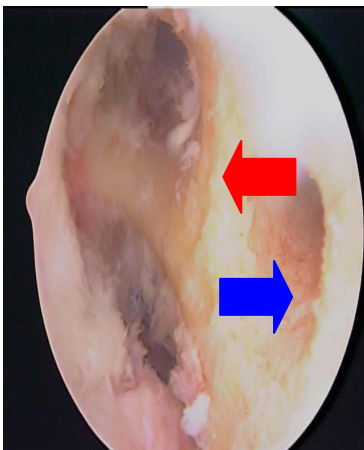


Figure 1. Femoral tunnels for anatomic double bundle ACL reconstruction. Note the previously placed vertical femoral socket (red arrow). The blue arrow shows the new socket for the PL bundle.

ACL Double-Bundle Reconstruction cont...

Rehabilitation

We rehabilitate our patients similar to a primary ACL reconstruction except with a slower timeline. Rehabilitation is customized to each individual patient, depending on other findings at surgery, particularly if any other concurrent procedures were performed. Return to cutting activities is limited for six months and sports are not allowed for 6-12 months and when functional studies show 90 percent functional capacity of the normal leg. It often takes up to 1 year for the athlete to perform at their previous level of activity.

Discussion

To date, no clinical studies have demonstrated that double bundle ACL reconstruction is superior to single bundle reconstruction. However, in light of the biomechanical evidence suggesting that this reconstruction provides superior rotational stability, the double bundle reconstruction may confer a theoretical advantage. We feel that in the revision situation, particularly in the instance of a vertically placed femoral socket, the addition of the posterolateral bundle is likely to provide better rotational stability than a single bundle alone.

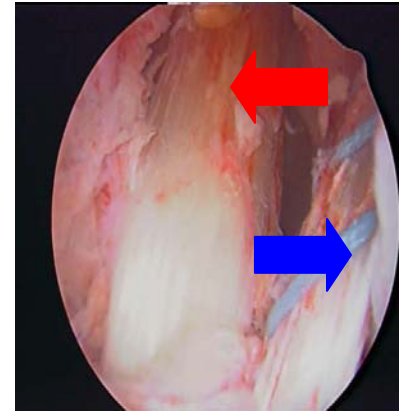
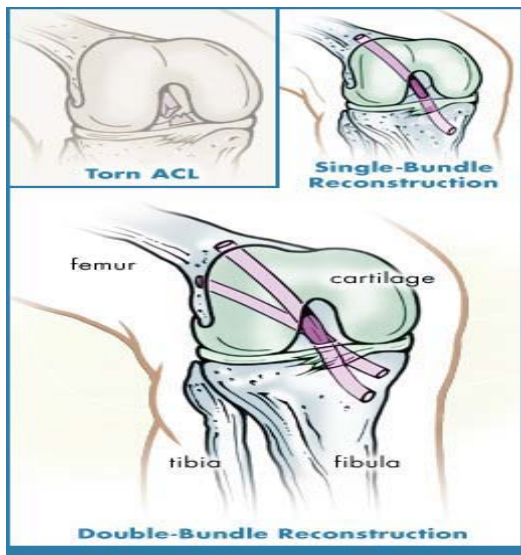


Figure 2. Anatomic double bundle ACL reconstruction. Red arrow demonstrates AM bundle and blue arrow demonstrates PL bundle

Meet our Sports Medicine Team

Our Physicians:

Darren Johnson, MD
 Scott Mair, MD
 Christian Lattermann MD
 Robert Hosey, MD
 Kyle Parish, MD

Our Athletic Trainers:

David Brajuha, ATC
 Kara Frey, ATC
 Greg Jackson, ATC
 David Jacobs, ATC
 Candi Lee, ATC
 Carrie McCloskey, ATC
 Sheri McNew, ATC
 Rob Ullery, ATC
 Tim Pike, ATC
 Jenni Williams, ATC

References

1. Boden B, Griffin L, Garnett W. Etiology and prevention of noncontact ACL injury. *The Physician and Sports Medicine*. 2000; 28(4): 1-14.
2. Feretti M, Zelle B, Fu F. Anatomic ACL double-bundle reconstruction. *Orthopedic Technology Review*. 2005; 7(4).
3. Kurosawa H, Yamakoshi K, Yasuda K, Sasaki T. Simultaneous measurement of changes in length of the cruciate ligaments during knee motion. *Clin Orthop*. 1991; 265: 233-240.
4. Woo SL, Kanamori A, Zeminski J, et al. The effectiveness of reconstruction of the anterior cruciate ligament with hamstrings and patellar tendon: a cadaveric study comparing anterior tibial and rotational loads. *JBJS*. 2002; 84A(6): 907-914.
5. Yagi M, Wong EK, Kanamori A, et al. Biomechanical analysis of an anatomic anterior cruciate ligament reconstruction. *Am J Sports Med*. 2002; 30(5): 660-666.

(859) 323-5533

www.mc.uky.edu/orthopaedics

Cardiovascular Screening in Athletes

Jennifer M. Hauk, MD

Introduction:

Sudden death in high school and collegiate athletes is fortunately rare but often occurs without warning. An estimated risk of sudden death in this population is approximately 1/100,000. Sudden death results from electrical instability with consequent fatal arrhythmias in athletes with underlying cardiac abnormalities performing intense exercise. Individuals generally at higher risk include those participating in basketball, football, track and soccer. Unfortunately, screening tools are limited in determining who is at the highest risk. A thorough personal and family history remains the most important aid in identifying those with pathologic cardiac disease.



Cardiac Etiologies:

Several rare causes of sudden cardiac death need to be considered when evaluating athletes. More common entities in the United States include hypertrophic cardiomyopathy (HCM) accounting for ~40%, Marfan's syndrome and congenital coronary artery anomalies. Less common entities include congenital QT prolongation, Wolff-Parkinson-White syndrome, arrhythmogenic right ventricular dysplasia, congenital aortic stenosis and viral myocarditis.

Non-cardiac Etiologies:

Chest pain in athletes is more commonly non-cardiac in origin. Asthma and exercise induced bronchospasm (EAB) are the most common non-cardiac causes of exertional symptoms and need to be considered particularly with an underlying history of allergies and eczema. Symptoms including chest tightness, dry cough and/or shortness of breath typically begin several minutes after starting activity or during recovery. Athletes may also encounter substernal chest pain, nausea, vomiting or cough with esophageal reflux. This may be more apparent in athletes undergoing more vertical motion including jumping and running. Another common etiology of chest pain is costochondritis that typically worsens with a deep breath and cough. Physical exam usually reveals focal tenderness.

Other causes to consider with exertional syncope include dehydration in humid conditions, exercise-associated collapse following complete cessation of strenuous exercise, hyperventilation and rarely hypoglycemia.



History:

A personal history of exertional chest pain, palpitations, syncope or dizziness is often unreported or not experienced with athletic activities. When reported, however, these symptoms with activity are particularly concerning. The most helpful information when screening athletes is an accurate family history for genetic abnormalities including HCM and history of sudden death at an early age (<35). A history of syncope also raises concern with conduction abnormalities in conditions such as congenital QT prolongation and Wolff-Parkinson-White syndrome. Additional information that may be helpful includes a personal history of rheumatic fever or previous cardiac disease or surgeries.

Questioning regarding non-cardiac etiologies include a history of allergies and eczema, dietary consumption and relation to exercise as well as recent history of fall or minor trauma. Additional questioning should include use of prescription medications and over-the-counter regimens. Stimulant medications, even in normal doses, may account for intermittent episodes of palpitations or chest pain with exertion.

Physical Examination:

During a pre-participation exam, some findings may be helpful when present. A standing position or Valsalva maneuver will increase an outflow obstruction and consequently a murmur in HCM. Murmurs may also be appreciated in athletic heart syndrome (AHS), which is an adaptive non-pathologic response to endurance training resulting in an increased ventricular volume and **generalized** wall thickness. Conversely, on physical exam, a murmur will decrease with standing and increase in the supine position.

Other physical exam findings may be helpful in detecting conditions such as Marfan's syndrome. Supportive physical findings include arachnodactyly (long fingers), scoliosis, high arched palate, lenticular dislocation and an increased arm span/height ratio.

Cardiovascular Screening continued

Evaluation:

Any athlete with history or physical exam findings needs further evaluation before considering athletic participation. Generally, an ECG is done initially with symptoms of chest pain. It is important to note that EKG findings of a well-conditioned athlete are variable secondary to increased vagal tone and physiologic hypertrophy. Findings **may** include sinus bradycardia, first or second-degree atrioventricular block, LV hypertrophy, and ST segment elevation with T wave inversion in the precordial leads. These changes typically normalize with cessation of regular exercise. Many athletes with pre-excitation syndromes and prolonged QT syndromes may have a normal ECG. In this case, an event monitor or exercise stress test may be helpful in identifying a pathological arrhythmia.

Echocardiography (ECHO) is beneficial in identifying septal hypertrophy, valvular abnormalities, and aortic dilation. When clinical suspicion is high for HCM, an ECHO is indicated to evaluate for septal hypertrophy and LV outflow tract obstruction. Asymmetrical septal hypertrophy greater than 13mm is concerning for HCM and may be difficult to differentiate from physiologic hypertrophy. Temporary cessation of training will result in diminished hypertrophy in AHS and remain unchanged in HCM helping to elucidate a diagnosis. If considering an anomalous coronary artery, cardiac consultation with possible cardiac catheterization may be necessary since an ECHO may not detect an abnormality.



Return to Play:

Returning to athletic participation should only be considered after a team physician or cardiologist completes an appropriate cardiac evaluation. Athletes with confirmed HCM are considered ineligible for sports except for low-static, low-dynamic exercise such as golf. Those with suspected arrhythmias require monitoring during exercise and typically echocardiography to exclude associated cardiac abnormalities before considering return to play if the athlete is asymptomatic. Athletes with myocarditis require rest from activities for approximately six months followed by echocardiography to ensure left ventricular function has returned to normal.

Alternative non-cardiac etiologies are a diagnosis of exclusion when clinical suspicion is high or there is a positive family history. After a normal evaluation, a trial of treatment directed at other causes may be tried before returning to full activity.

References:

1. Beckerman J, Wang P, Hlatky M. Cardiovascular Screening of Athletes. Clin J Sport Med. 2004; 14: 127-33.
2. Rowland TW. Evaluating Cardiac Symptoms in the Athlete: Is it Safe to Play? Clin J Sport Med. 2005; 15: 417-20.
3. Basilio FC. Cardiovascular Disease in Athletes. Amer J Sport Med. 1999; 27: 108-21.

MRSA What Is It?

MRSA is a staph bacteria that is resistant to common types of antibiotics. Staph bacteria are one of the most common causes of skin infections and can cause pneumonia, surgical wound infections and bloodstream infections. These can become life-threatening infections if not treated properly. The majority of MRSA infections occur among patients in hospitals or other healthcare settings. Recently, it has become more common in the community setting.

What does MRSA infection look like?

Staph infections often begin with an open wound- allowing the bacteria to enter the body and develop into an infection. Look for:

- Pimples, boils, or blisters which become red, swollen, painful, or have pus or other drainage
- Sometimes mistaken for spider bites
- Some people may have chills, fever, feel nauseous and have acute pain

Is MRSA infection treatable?

Most staph and MRSA infections are treatable with antibiotics. If you go to your physician with a possible infection, ask them to culture the infection so they know what type of antibiotic to put you on.

Take all of the doses of the antibiotic, even if the infection is getting better. Do not stop unless your physician tells you to. Do not share antibiotics with other people or save unfinished antibiotics to use at another time.

Drainage of skin boils or abscesses should only be done by a physician. DO NOT attempt to squeeze or drain a boil yourself. This will only spread the infection.

How to prevent MRSA or staph infection.

MRSA or staph infections are spread through physical contact or touching surfaces the infection has come in contact with- i.e., sports equipment, weight equipment, tables, lockers.

What is MRSA? Continued

PRACTICE GOOD HYGIENE!

- Keep your hands clean by washing thoroughly with soap and water or using an alcohol-based hand sanitizer
- Clean ALL cuts and scrapes daily with soap and water. Put over the counter triple antibiotic ointment on the wound and cover. This is especially important during physical activity when you are around other people. Keep wound covered daily until it is totally healed.
- AVOID contact with other people's wounds or discarded bandages.
- AVOID sharing personal items such as towels, clothing, razors.
- DO NOT share equipment if it has not been wiped down first with an alcohol based sanitizer.
- Shower after practices or games.
- Take practice clothing home every night and wash it in hot water with detergent. Dry on a hot setting. Do not wear dirty clothing for practice or games.
- Wash sheets, towels or clothing at home that has come in contact with your open wound.



Meet Christian Lattermann M.D.

is an Assistant Professor of Orthopaedics and Sports Medicine at the University of Kentucky. Dr. Lattermann received his medical degree from the Hannover Medical School, Hannover, Germany. He completed his residency at the Department of Trauma Surgery, also at the Hannover Medical School, and completed a sports medicine fellowship at the University of Pittsburgh. He serves as team physician for the University of Kentucky and Eastern Kentucky University athletic teams.

UK Sports Medicine Walk-In

- With our sports injury walk-in clinic, no appointment is necessary.
- Walk-in at 7:30 - 8am.
- We're located within Kentucky Clinic, with adjacent parking available.
- Staffed by sports medicine fellowship-trained physicians.
- Physical therapy and rehabilitation services are available.
- We're proud to be the team physicians for all UK Athletics.
- Call (859) 257-4577 for more information.



