

# **Sports Medicine Update:**

## **What is New in the Treatment of Focal Chondral Defects of the Knee?**

**Christian Lattermann<sup>1</sup>, MD; Richard W. Kang<sup>2</sup>, BS; Brian J. Cole, MD<sup>3</sup>**

1) University of Kentucky Medical Center  
Orthopaedic Sports Medicine  
Lexington Kentucky

2) Rush Presbyterian University  
Orthopaedic Sports Medicine  
Chicago, Illinois

3) Associate Professor  
Director of Cartilage Restoration Center  
Rush Presbyterian University  
Chicago, Illinois

Reprint Requests to:  
Christian Lattermann, MD  
Assistant Professor for Orthopaedic Sports Medicine  
Director: Cartilage Repair Center  
Kentucky Clinic, Suite K401  
740 South Limestone  
Lexington, KY 40536-0284  
Email: Clattermann@gmail.com

## **Introduction**

Articular cartilage injuries in the knee have been recognized as a cause for significant morbidity and disability since the early 19<sup>th</sup> century<sup>1</sup>. Each year it is estimated that chondral lesions affect up to 900,000 individuals in the United States resulting in over 200,000 surgical procedures, most of which are diagnostic arthroscopies and simple debridements<sup>2</sup>. The use of arthroscopic techniques has enhanced the ability to detect and determine the extent of isolated or combined cartilage injuries following ligament tears or articular fractures. While it is generally accepted that focal chondral lesions often progress towards osteoarthritis, a review of the literature presents compelling evidence that between 11% and 40% of all patients under the age of 40 undergoing arthroscopic surgery for other reasons have treatable chondral injuries that will remain unaddressed<sup>3,4,5</sup>. Chondral and osteochondral restoration treatment techniques are relatively new and rapidly evolving, and represent a tremendous potential to restore functionality in predominantly younger patients. The treatment algorithms for these injuries are complex and often involve multiple procedures such as marrow stimulation, cell transplantation, and osteochondral grafting and bony corrections such as osteotomies.

The aim of this article is to review the current articular cartilage restoration techniques and their published results and introduce the reader to the concept of patient profiling, improved imaging technology, and emerging technologies that may soon become available to the US market.

### **Diagnosis and Classification of Cartilage injuries:**

Patient history, physical examination, X-rays and magnetic resonance imaging are usually sufficient to diagnose a cartilage injury. It is important to differentiate patients that have isolated or multiple focal chondral lesions from patients with diffuse osteoarthritic changes. Patients with focal chondral defects (FCDs) usually have normal range of motion and possibly focal tenderness over palpable areas along the lateral or medial femoral condyle during exam. Activity-related effusions may also be present. Patients with FCDs are usually young, active and can carry out activities of daily living (ADL), although they will often report activity-specific pain (i.e., symptoms during deep squatting, cutting). However, accompanying injuries and bony malalignment are common in patients with FCDs and need to be carefully assessed and documented since these affect the decision-making regarding treatment options. Patients with more diffuse cartilage damage usually show a subtle decrease in ROM (flexion earlier than extension). They often present with chronic effusions, and more diffuse rather than focal pain during their ADL. These patients continue to represent a treatment challenge as they are often less responsive to cartilage repair techniques.

Classification of articular cartilage injuries has been difficult due to the lack of objective measurements. The Outerbridge classification is the most widely used classification system to describe the size of a cartilage lesion<sup>6</sup>. It provides a distinction between a partial (Grades 1 and 2) vs. nearly-full or full thickness cartilage defect (Grades 3 and 4); between a small (Grade 2) and larger (Grade 3) lesion; and describes a complete loss of cartilage (Grade 4). The Outerbridge classification has, however, specific limitations. For example, a 4 cm by 3 cm partial thickness defect with a potentially bad prognosis due to its size is classified as a grade 1 defect, whereas a direct cut or narrow fissure is classified as a grade 4 defect. These limitations have prompted the International Cartilage Repair Society (ICRS) to introduce a modified classification system that focuses on the depth of the cartilage injury (Fig 1). Combined with visual measurement, the modified ICRS classification has the potential to better describe the defect macroscopically and correlates better with clinical outcome<sup>7</sup>.

Plain radiographs effectively aid the diagnosis and evaluation of osteoarthritis or chondropenia. The standard cartilage x-ray series for the knee should include the

bilateral standing antero-posterior, the 45-degree flexion-weight bearing postero-anterior, and the non-weight bearing lateral and patella sunrise views. Subtle joint space narrowing, subchondral sclerosis, osteochondral defects, as well as osteophytes and cysts can easily be identified on these views.

Although the use of MRI imaging is best used in the assessment of concomitant injuries, special articular cartilage sequences can be obtained to aid the diagnosis and evaluation of cartilage injury. It should be appreciated, however, that while these sequences are helpful to assess large focal chondral defects, they generally underestimate the extent of the actual chondral injury. More recently, novel MRI imaging techniques such as the delayed Gadolinium-Enhanced MRI of Cartilage (dGEMRIC) and T2 relaxation time mapping, hold great promise in the evaluation of articular cartilage. dGEMRIC is a noninvasive imaging technique that visualizes the glycosaminoglycan (GAG) content in cartilage<sup>8</sup> and effectively aids in the evaluation of early knee osteoarthritis<sup>9</sup> and cartilage health, subsequent to ligament rupture<sup>10</sup>. dGEMRIC also provides measurement of compressive stiffness following cartilage repair procedures<sup>11,12</sup>. Another technique, T2 relaxation time mapping, can be used to measure the collagen content of cartilage. This MRI parameter represents the internuclear relaxation secondary to the transverse relaxation of excited hydrogen dipoles<sup>13</sup>. T2 has demonstrated potential usefulness in the determination of histological degeneration of cartilage, provides the ability to map anatomical zones of cartilage, and the longitudinal evaluation of cartilage from the time of injury, to determine optimal surgical intervention, if needed<sup>14</sup>. Importantly, dGEMRIC and T2 mapping provide noninvasive means to detect early matrix changes before discernable morphologic alteration. Thus, they have significant potential to help ascertain the extent of cartilage damage, and will provide objective information towards the determination an optimal window of treatment using effective cartilage restoration procedures.

### **Current treatment techniques:**

Various techniques have been described and are in use that attempt to promote the regeneration of articular cartilage. While none of the currently available techniques result in full regeneration of articular cartilage, it is important nonetheless to understand the

technical differences and nuances between them in order to maximize their clinical efficacy. Additionally, a broader understanding of cartilage restoration techniques and their associated outcomes will assist the reader in appreciating the direction of emerging technologies in cartilage repair.

### **Microfracture:**

Microfracture is a technique that utilizes controlled subchondral perforations that allow marrow elements (mesenchymal cells, growth factors) to accumulate in the chondral defect. The perforations initiate the formation of a “superclot” that forms at the time of surgery, which then remodels over the course of 6-12 months into a fibrocartilaginous repair tissue. Although the repair tissue consists predominantly of collagen type I and resembles fibrocartilage more than hyaline cartilage (*e.g.* the repair tissue does not resist shear and compression loads as predictably as normal hyaline cartilage), overall, microfracture is a low morbidity procedure. This technique is a widely used and well documented treatment option. If done correctly it has great potential for symptomatic improvement: recent examples of favorable outcomes include (1) a report by Steadman *et al* summarizing 11 years of experience of significant subjective improvement in treated patients<sup>15</sup>, and a report by Gobbi *et al* documenting subjective and objective improvements in 109 patients at an average of 72 months follow-up<sup>16</sup>. Additional reports include a case series by Mithoefer *et al*, consisting of 20 patients with focal chondral defects of varying sizes; 61% of these patients were participating in professional or highly competitive cutting / pivoting sports at the time of injury. Following microfracture treatment, up to 47% of patients continued participation in sports, but only 20% at the pre-injury level. Notably, this study concluded that younger patients (< 40 years) with lesions less than 200mm<sup>2</sup> and pre-operative symptoms of less than 12 months return to sports activities in significantly higher numbers than other patients<sup>17</sup>. In an earlier study the same authors could show that high body-mass index (>30) and duration of symptoms are negative predictive factors for a good outcome<sup>18</sup>. In a similar study, Kreuz *et al* compared 18 versus 36 months follow-up outcomes in 85 patients following microfracture treatment of various size defects using the Cincinnati and ICRS scoring systems<sup>19</sup>. Essentially, this study demonstrated that at 18 months post

procedure, patients with condylar defects maintain their scores whereas patients with other defect localizations significantly deteriorate. This study also corroborates Mithoefer *et al*'s findings that patients over the age of 40 have significantly lower outcome scores at all time points.

Microfracture therapy is often chosen as the benchmark for which to compare other cartilage repair procedures. Knutsen *et al.* found no significant differences between microfracture treatment and autologous chondrocyte implantation (ACI) at two years follow up<sup>20</sup> in a prospective randomized clinical trial utilizing the Tegner as well as the IKDC scoring systems. Basad *et al.* also reported no significant differences in the Tegner, Lysholm or IKDC scores between microfracture and the matrix-guided ACI (MACI) at 24 months follow-up<sup>21</sup>.

Despite its relative success, a contraindication to microfracture is a patients' unwillingness or inability to undergo the necessary post-operative rehabilitation which typically requires a period of 4 to 6 weeks of protected weight bearing and continuous passive motion.

### **Autologous chondrocyte Implantation (ACI):**

ACI is a cartilage restorative procedure in which a small amount (200-300 mg) of healthy, autologous cartilage is harvested from the patient, typically during an initial arthroscopic evaluation of the chondral lesion. The tissue is then enzymatically treated in the laboratory to release chondrocytes, followed by isolation, purification, and expansion before reimplantation into the lesion. The goal of ACI is to restore hyaline cartilage (>90% collagen type II). Histological studies and direct enzymatic quantitative measurements have demonstrated that ACI produces a "hyaline-like cartilage" with a collagen type II content of between 35% and 55%. This repair tissue may have possibly greater, more authentic biomechanical properties than the fibro cartilage regenerated in similar lesions repaired by chondroplasty or microfracture.

Since the initial report by Brittberg *et al.*<sup>22</sup> describing ACI, this technique has been adopted worldwide to treat cartilage defects in humans. Although Peterson *et al.* initially reported an overall success rate of 89% for isolated femoral lesions two to nine years following ACI treatment, a lower success rate (62%) was seen in high pressure

areas such as the patella<sup>23</sup>. There is anecdotal evidence for improved outcomes for the treatment of the patellofemoral joint if an antero-medialization osteotomy was added<sup>24</sup>. Bentley *et al.* demonstrated in a randomized clinical trial that ACI compares favorably with autologous chondral plugs (MOSAIC-plasty) at one year follow-up. Although they reported 88% good and excellent results (Cincinnati score) for ACI treatment of defects on the medial femoral condyle, these encouraging results could not be duplicated with patellar, trochlear or lateral condylar defects<sup>25</sup>.

The ideal indication for ACI is the symptomatic, unipolar, well contained defect between 2 and 10 cm<sup>2</sup> that does not violate the subchondral bone. ACI is often performed in patients that failed traditional first-line treatments such as debridement, microfracture, or osteochondral autograft techniques. Contraindications for this procedure are bipolar lesions and lesions with significant bone loss. As for any of the cartilage restoration procedures it is imperative that concomitant malalignment, ligament instability and meniscus deficiency are corrected prior to or at the time of index surgery. The most common complication of ACI is hypertrophy of the regenerating tissue (up to 20%), possibly related to the periosteum patch used in this procedure<sup>25</sup>. This complication can be successfully treated with an arthroscopic debridement. Rehabilitation following ACI is similar to that which is required following microfracture.

### **Osteochondral grafts:**

Osteochondral grafting, the direct transplantation of an osteochondral autograft or allograft, is the only technique available that restores hyaline cartilage. Autograft plugs are typically used to treat relatively small defects (*e.g.* up to 20 mm<sup>2</sup>), due to donor site size limitations. Osteochondral allografts can be harvested up to 35mm in diameter; greater allografts can be obtained if a hand-fashioned “shell” grafting technique is utilized. Any allograft technique typically involves the preparation of the recipient site as well as the donor plug using a coring reamer or drill. While osteochondral autograft procedures are limited by potential donor site morbidity, osteochondral allografts pose the risk of disease transmission and a possible graft versus host immune response against the donor tissue. Therefore, a fresh osteochondral allograft should be implanted only after its sterility and lack of transmissible diseases has been verified. Maximal

chondrocyte viability is maintained in grafts implanted no greater than 28 days post harvest (Cole BJ, *Journal of Orthopaedic Research* accepted for publication 2006)

Clinical outcome of osteochondral autografts has been documented in various studies. Hangody *et al.* reported good or excellent results in 79% of patellofemoral lesions, 87% of tibial lesions and 92% of isolated femoral lesions treated with osteochondral autograft plugs (MOSAIC plasty)<sup>26</sup>. Emerging reports of osteochondral autografts use in other joints have been promising, and include the treatment of the talus<sup>27</sup>, femoral head<sup>26</sup>, and elbow<sup>28</sup>.

Osteochondral allografting has generally been best for younger patients with isolated traumatic lesions or osteochondritis dissecans. In 1985, McDermott and colleagues reported outcomes of their first 100 osteochondral allograft procedures, in which only 56% of patients demonstrated a good or excellent result at a mean of 3.8 years follow-up<sup>29</sup>. Results have since improved, benefiting from more careful patient selection and advances in allograft processing procedures, surgical technique, and postoperative rehabilitation. Sasha *et al.* reported a 10 years graft survival rate of 71% and a 20 years survival rate of 66%<sup>30</sup>. In the experience of the senior author of this review article (BJC), his patients have reported an overall 84% satisfaction rating, with significant improvements in the IKDC and KOOS at 2 years follow-up. Eighty-eight percent of the osteochondral allografts were radiographically incorporated at clinical follow-up (BJC unpublished data).

### **Where are we today?**

Cartilage repair continues to be an emerging field with tremendous treatment potential for predominantly young and active patients. While some of the more advanced, but currently considered experimental techniques, may revolutionize the field in years to come, it is important to optimize the current treatment options for the benefit of our patients. For this reason it is important to clearly identify the appropriate indications, contra-indications, and to optimize patient selection and manage all co-morbidities. This “patient profiling” assures the best possible outcome for each patient on an individual basis and prevents unrealistic expectations.

Krishnan and Bentley investigated the prognostic indicators for ACI reporting that younger patients with high pre-operative scores, less than two-year history of symptoms, a single defect, trochlear or femoral condylar defects and fewer than 2 previous surgical procedures are positive outcome predictors. Revision ACI in previously failed ACI and mosaic plasties showed significantly inferior results to primary procedures <sup>31</sup>.

Over the last decade clinical and basic science research has provided us with the foundation for the successful treatment of focal cartilage defects. While techniques such as microfracture, ACI and osteochondral grafts can restore function to most patients there are pitfalls with any one of these techniques. Microfracture and ACI do not restore hyaline cartilage and therefore may have limited durability. Osteochondral grafts fail to incorporate at the cartilage interface and have shown a propensity to degenerate in pre-clinical and clinical follow-up, thus may also fail at midterm evaluation. True long-term studies assessing any of these techniques for the treatment of focal chondral defects have not been published. Good to excellent mid-term results are reported in the majority of our patients; however, there are patients who fail the initial procedure. It is therefore crucial to establish a treatment algorithm that considers the potential for failure and yet, does not preclude secondary treatment options. We have developed a comprehensive treatment algorithm that is delineated in Figure 2 (Fig 2). This algorithm assures a treatment protocol that is based on clinical symptoms and enables us to offer appropriate surgical intervention without burning bridges for further treatment options.

### **Emerging Ideas / Techniques:**

The currently established, FDA approved techniques provide the foundation but also the benchmark for novel techniques (Fig 3). New emerging techniques focus on the restoration of articular cartilage based upon the delivery of autologous or allogeneic chondrocytes or stem cells to the focal chondral defect. ACI opened the door to this technology by proving clinical success and showing the limitations and complications of this procedure. Novel techniques therefore try to circumvent the tedious process of having to manually sew a chamber with locally harvested periosteum. The easiest way to avoid the periosteum harvest is to utilize a collagen membrane, as shown by Bentley *et al.* with their ACI-C technique: success rates were comparable to that of classic ACI

with a lower incidence of chondral hypertrophy. This technique may therefore eliminate one problem facing surgeons in up to 20% of their patients when utilizing traditional ACI technology<sup>32</sup>. Other investigators have seeded chondrocytes directly onto a membrane that acts as a scaffold for the chondrocytes (MACI, Hyalograft C). These scaffold membranes are naturally “sticky” and can be positioned into the defect arthroscopically without additional fixation, and theoretically possess the advantage that chondrocytes can expand in three-dimensional scaffold. This scaffold may allow the chondrocytes to lay down competent matrix prior to implantation, “kick-starting” the process of hyaline or hyaline like cartilage formation. To date, some of these techniques have demonstrated comparable results to ACI<sup>33-36</sup>, although they are not currently FDA approved. Other groups have recently cultured a scaffold seeded with autologous chondrocytes inside a bioreactor that continuously applies hydrostatic pressure to the scaffold (Neocart, Histogenics, Northampton MA), and is currently under investigation in a clinical trial.

A different angle has been investigated by a group in Norway. They noted that subgroups of harvested autologous chondrocytes have a higher potential to proliferate than others, and have developed a mechanism to selectively culture the more potent chondrocytes for re-implantation (ChondroCelect, Tigenix Inc., Leuven, Belgium)<sup>37</sup>.

The previously mentioned techniques all depend upon the harvest of autologous chondrocytes and subsequent re-implantation, requiring two surgical procedures. A different approach has been described by Cole et al. They utilized minced donor cartilage placed on a bioabsorbable scaffold. This construct is then stapled into the focal chondral defect. The advantage of this cartilage autograft implantation system (CAIS, Depuy-Mitek, Norwood MA) is that it utilizes autologous cells and only involves a single surgical procedure<sup>38</sup>.

Further on the horizon are tissue engineering concepts that involve genetic manipulation of donor or recipient cells utilizing gene-therapy or growth factor therapies. Different scaffolds are being investigated for their suitability to restore articular cartilage. Over the next few years we will see an advent of new tissue-engineered technologies that may provide the opportunity to fully restore articular cartilage in focal chondral defects and will bring us closer to treating osteoarthritis with biologic means.

## **Literature:**

1. Hunter W. On the Structure and Diseases of Articulating Cartilage. Philos Trans R Soc Lond B Biol Sci. 1743;9:267.
2. Curl WW, Krome J, Gordon ES, Rushing J, Smith BP, Poehling GG. Cartilage injuries: a review of 31,516 knee arthroscopies. Arthroscopy. 1997 Aug;13(4):456-60.
3. Alford JW, Cole BJ. Cartilage restoration, part 1: basic science, historical perspective, patient evaluation, and treatment options. Am J Sports Med. 2005 Feb;33(2):295-306.
4. Aroen A, Loken S, Heir S, Alvik E, Ekeland A, Granlund OG, Engebretsen L. Articular cartilage lesions in 993 consecutive knee arthroscopies. Am J Sports Med. 2004 Jan-Feb;32(1):211-5.
5. Hjelle K, Solheim E, Strand T, Muri R, Brittberg M. Articular cartilage defects in 1,000 knee arthroscopies. Arthroscopy. 2002 Sep;18(7):730-4.
6. Outerbridge RE. The Etiology of Chondromalacia patellae. J Bone Joint Surg Br. 1961;43:752-9
7. Kleemann RU, Krockner D, Cedraro A, Tuischer J, Duda GN. Altered cartilage mechanics and histology in knee osteoarthritis: relation to clinical assessment (ICRS Grade). Osteoarthritis Cartilage. 2005 Nov;13(11):958-63.
8. Trattnig S, Millington SA, Szomolanyi P, Marlovits S. MR imaging of osteochondral grafts and autologous chondrocyte implantation. Eur Radiol. 2006 Jun 27

9. Tiderius CJ, Tjornstrand J, Akeson P, Sodersten K, Dahlberg L, Leander P.  
Delayed gadolinium-enhanced MRI of cartilage (dGEMRIC): intra- and interobserver variability in standardized drawing of regions of interest.  
Acta Radiol. 2004 Oct;45(6):628-34.
10. Young AA, Stanwell P, Williams A, Rohrsheim JA, Parker DA, Giuffre B et al.  
Glycosaminoglycan content of knee cartilage following posterior cruciate ligament rupture demonstrated by delayed gadolinium-enhanced magnetic resonance imaging of cartilage (dGEMRIC). A case report.  
J Bone Joint Surg Am. 2005 Dec;87(12):2763-7.
11. Kurkijarvi JE, Nissi MJ, Kiviranta I, Jurvelin JS, Nieminen MT  
Delayed gadolinium-enhanced MRI of cartilage (dGEMRIC) and T2 characteristics of human knee articular cartilage: topographical variation and relationships to mechanical properties. Magn Reson Med. 2004 Jul;52(1):41-6.
12. Gillis A, Bashir A, McKeon B, Scheller A, Gray ML, Burstein D.  
Magnetic resonance imaging of relative glycosaminoglycan distribution in patients with autologous chondrocyte transplants.  
Invest Radiol. 2001 Dec;36(12):743-8.
13. Maier CF, Tan SG, Hariharan H, Potter HG.  
T2 quantitation of articular cartilage at 1.5 T.  
J Magn Reson Imaging. 2003 Mar;17(3):358-64.
14. Potter HG, Foo LF.  
Magnetic resonance imaging of articular cartilage: trauma, degeneration, and repair. Am J Sports Med. 2006 Apr;34(4):661-77.
15. Steadman JR, Briggs KK, Rodrigo JJ, Kocher MS, Gill TJ, Rodkey WG.  
Outcomes of Microfracture for Traumatic Chondral Defects of the Knee: 11-year Follow-up. Arthroscopy. 2003;19:477-84

16. Gobbi A, Nunag P, Malinowski K.  
Treatment of Full Thickness Chondral Lesions of the Knee with Microfracture in a group of Athletes. *Knee Surg Sports Traumatol Arthrosc* 2005;13:213-221
17. Mithoefer K, Williams RJ 3rd, Warren RF, Potter HG, Spock CR, Jones EC et al.  
The microfracture technique for the treatment of articular cartilage lesions in the knee. A prospective cohort study.  
*J Bone Joint Surg Am.* 2005 Sep;87(9):1911-20.
18. Mithoefer K, Williams RJ 3rd, Warren RF, Wickiewicz TL, Marx RG.  
High-Impact Athletics After Knee Articular Cartilage Repair: A Prospective Evaluation of the Microfracture Technique. *Am J Sports Med.* 2006 May 30
19. Kreuz PC, Steinwachs MR, Erggelet C, Krause SJ, Konrad G, Uhl M et al. Results after microfracture of full-thickness chondral defects in different compartments in the knee. *Osteoarthritis Cartilage.* 2006 Jun 29 (epub ahead of print)
20. Knutsen G, Engebretsen L, Ludvigsen TC, Drogset JO, Grontvedt T, Solheim E et al.,  
Autologous chondrocyte implantation compared with microfracture in the knee. A randomized trial. *J Bone Joint Surg Am.* 2004 Mar;86-A(3):455-64.
21. Wasiak J, Clar C, Villanueva E  
Autologous cartilage implantation for full thickness articular cartilage defects of the knee. *Cochrane Database Syst Rev.* 2006 Jul 19.
22. Brittberg M, Lindahl A, Nilsson A, Ohlsson C, Isaksson O, Peterson L.  
Treatment of deep cartilage defects in the knee with autologous chondrocyte transplantation. *N Engl J Med.* 1994 Oct 6;331(14):889-95.
23. Peterson L, Minas T, Brittberg M, Nilsson A, Sjogren-Jansson E, Lindahl A.  
Two- to 9-year Outcome After Autologous Chondrocyte Implantation of the Knee. *Clin Orthop Rel Res* 2000. 374:212-34

24. Beck PR, Thomas AL, Farr J, Lewis PB, Cole BJ.  
Trochlear contact pressures after anteromedialization of the tibial tubercle.  
Am J Sports Med. 2005 Nov;33(11):1710-5.
25. Bentley G, Biant LC, Carrington RW, Akmal M, Goldberg A, Williams AM et al. A  
prospective, randomised comparison of autologous chondrocyte implantation versus  
mosaicplasty for osteochondral defects in the knee.  
J Bone Joint Surg Br. 2003 Mar;85(2):223-30.
26. Hangody L, Fules, P.  
Autologous osteochondral mosaicplasty for the treatment of full-thickness defects of  
weight-bearing joints: ten years of experimental and clinical experience.  
J Bone Joint Surg Am, 85-A Suppl 2: 25-32, 2003.
27. Hangody L, Kish G, Modis L, et al.  
Mosaicplasty for the Treatment of Osteochondritis Dissecans of the Talus: Two to Seven  
Year Results in 36 Patients.  
Foot Ankle Int. 2001;22:552-8
28. Bradley JP, Petrie RS.  
Osteochondritis Dissecans of the Humeral Capitulum: Diagnosis and Treatment.  
Clin Sports Med. 2001;20:565-90
29. McDermott AG, Langer F, Pritzker KP, Gross AE.  
Fresh small-fragment osteochondral allografts. Long-term follow-up study on first 100  
cases. Clin Orthop Relat Res. 1985 Jul-Aug;(197):96-102.
30. Shasha N, Aubin PP, Cheah HK, Davis AM, Agnidis Z, Gross AE.  
Long-term clinical experience with fresh osteochondral allografts for articular knee  
defects in high demand patients.  
Cell Tissue Bank. 2002;3(3):175-82.

31. Krishnan SP, Skinner JA, Bartlett W, Carrington RW, Flanagan AM, Briggs TW et al.  
Who is the ideal candidate for autologous chondrocyte implantation?  
J Bone Joint Surg Br. 2006 Jan;88(1):61-4.
32. Krishnan SP, Skinner JA, Carrington RW, Flanagan AM, Briggs TW, Bentley G.  
Collagen-covered autologous chondrocyte implantation for osteochondritis dissecans of the knee: two- to seven-year results.  
J Bone Joint Surg Br. 2006 Feb;88(2):203-5.
33. Behrens P, Bitter T, Kurz B, Russlies M.  
Matrix-associated autologous chondrocyte transplantation/implantation (MACT/MACI)--  
5-year follow-up.  
Knee. 2006 Jun;13(3):194-202.
34. Bartlett W, Skinner JA, Gooding CR, Carrington RW, Flanagan AM, Briggs TW et al.  
Autologous chondrocyte implantation versus matrix-induced autologous chondrocyte implantation for osteochondral defects of the knee: a prospective, randomized study.  
J Bone Joint Surg Br. 2005 May;87(5):640-5.
35. Gobbi A, Kon E, Berruto M, Francisco R, Filardo G, Marcacci M.  
Patellofemoral Full-Thickness Chondral Defects Treated With Hyalograft-C: A Clinical, Arthroscopic, and Histologic Review.  
Am J Sports Med. 2006 Jul 10; [Epub ahead of print]
36. Marcacci M, Berruto M, Brocchetta D, Delcogliano A, Ghinelli D, Gobbi A et al.  
Articular cartilage engineering with Hyalograft C: 3-year clinical results.  
Clin Orthop Relat Res. 2005 Jun;(435):96-105.
37. De Bari, C., et al.  
Multipotent mesenchymal stem cells from adult human synovial membrane.  
Arthritis Rheum. 44.8 (2001): 1928-42.

38. Lu Y, Dhanaraj S, Wang Z, Bradley DM, Bowman SM, Cole BJ, Binette F. Minced cartilage without cell culture serves as an effective intraoperative cell source for cartilage repair.

J Orthop Res. 2006 Jun;24(6):1261-70.

**Figure Legends:**

Fig.1)

**Title:** ICRS Classification of Cartilage Injuries

**Legend:** ICRS Classification based upon the Outerbridge classification<sup>6</sup>

Fig.2)

**Title:** Treatment Algorithm for the treatment of focal chondral defects

**Legend:** This treatment algorithm allows for a careful approach towards treating focal chondral defects avoiding to burn bridges for possible further treatment in the event of failure of the primary treatment option

Fig.3)

**Title:** Current Treatment Options for Focal Chondral Defects

**Legend:** The grey triangle depicts the currently FDA approved treatment options for FCD's. The white area depicts the emerging new technologies. Many of these new technologies are currently approved for clinical use in Europe (ACI-C, MACI, Hyalograft C, ChondroCelect). Some are currently undergoing phase-2 clinical trials in the United States (Neocart, CAIS).

Figure 1a)

ICRS grading Score<sup>7</sup>:

Grade	Property
1	superficial lesions, fissures, cracks, indentations
2	Fraying, lesions extending down to <50% of cartilage depth
3	Partial loss of cartilage thickness, cartilage defects extending down >50% of cartilage depth as well as down to calcified layer
4	Complete loss of cartilage thickness, bone only

Figure 2)

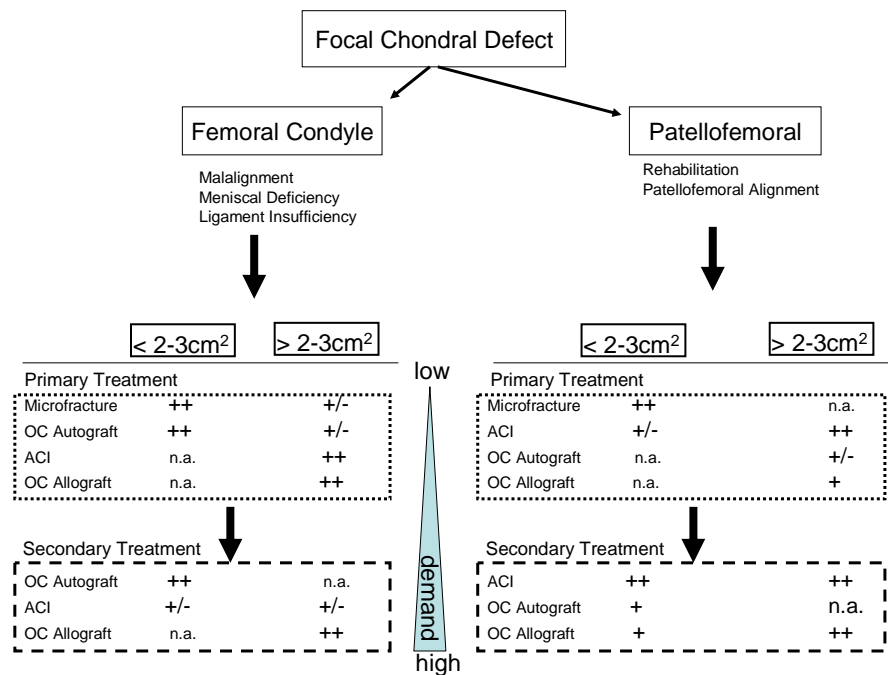


Figure 3)

